



Physics of Imaging Systems (ROE, CT, MRI)

Prof. Dr. Lothar Schad



Chair in Computer Assisted Clinical Medicine
Faculty of Medicine Mannheim
University of Heidelberg
Theodor-Kutzer-Ufer 1-3
D-68167 Mannheim, Germany
Lothar.Schad@MedMa.Uni-Heidelberg.de
www.ma.uni-heidelberg.de/inst/cbtm/ckm/



COMPUTER
ASSISTED
CLINICAL
MEDICINE



[Home](#)
[Staff](#)
[Research](#)
[Publications](#)
[Links](#)
[Lectures](#)
[Contact](#)

[Home](#) | [Contact](#) | [German](#)

[Home](#) >

Lectures

Our group is involved in the following study courses:

- Medical Physics
- MaReCum
- HeiCuMed

The list of current lectures and their schedule can be found in the LSF.

Accompanying Materials to our Lectures

- **Medical Physics: Physics of Imaging Systems**
 - Introduction
 - Röntgen 1
 - Röntgen 2
 - Röntgen 3
 - Computer Tomography 1
 - Computer Tomography 2
 - Computer Tomography 3
 - MRI 1
 - MRI 2
 - MRI 3
 - MRI 4
 - MRI 5
 - MRI 6
 - MRI 7



Introduction



Nobel Prize is awarded for MRI technology landmark achievement transformed healthcare in 20th century



**Press Release: The 2003 Nobel Prize in Physiology
or Medicine**

6 October 2003

The Nobel Assembly at Karolinska Institutet has today
decided to award The Nobel Prize in Physiology or
Medicine for 2003
jointly to

Paul C Lauterbur and **Peter Mansfield**

for their discoveries concerning
"magnetic resonance imaging"



Paul Lauterbur
(1929 - 2007)



Sir Peter Mansfield
(1933 -)

Diagnostic Imaging: Milestones



1901

W. C. Röntgen (Germany, 1845 - 1923)
discovery of X-rays



1952

Felix Bloch (USA, 1905 - 1983)
Edward M. Purcell (USA, 1912 - 1997)
development of a new precision method of nuclear magnetism (NMR)



1979

Allan M. Cormack (USA, 1924 - 1998)
Godfrey N. Hounsfield (UK, 1919 -)
development of Computer-Tomography (CT)



1991

Richard R. Ernst (CH, 1933 -)
development of high resolution magnetic resonance spectroscopy (MRS)




2003

Paul C. Lauterbur (USA, 1929 - 2007)
Peter Mansfield (UK, 1933 -)
development of magnetic resonance imaging (MRI)


Diagnostic Imaging: Pioneers



ROE



PET



“The Making of a Science”

CT



MRI





Motivation

Why do we need imaging systems ?

„Addiction“ to image information ?



source: Siemens "100 Jahre Röntgen" 1995



Information Flow of Sense Organs

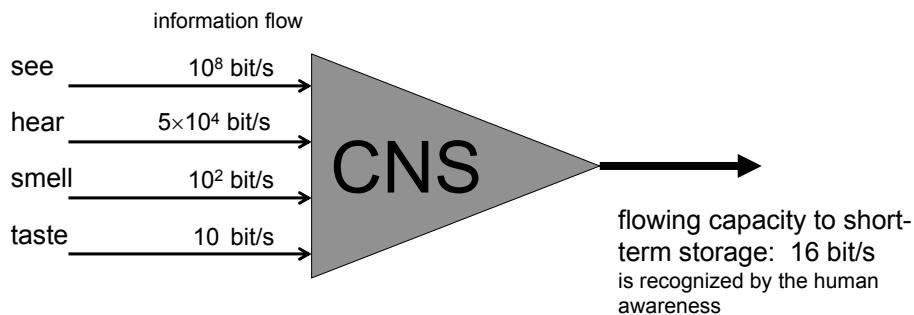
- information recording of all sense organs from our surroundings: $\approx 10^9$ bit/s

self-aware data processing: 100 bit/s

short-term storage: 10 bit/s

long-term storage: 1 bit/s

→ selection and filtering 1:10 million !



source: Drischel, „Einführung in die Biokybernetik“, Akademie-Verlag 1972

Conclusion



Imaging Systems are
supporting the most effective
and powerful sensor !

Physicians' Ranking of Innovations 2001

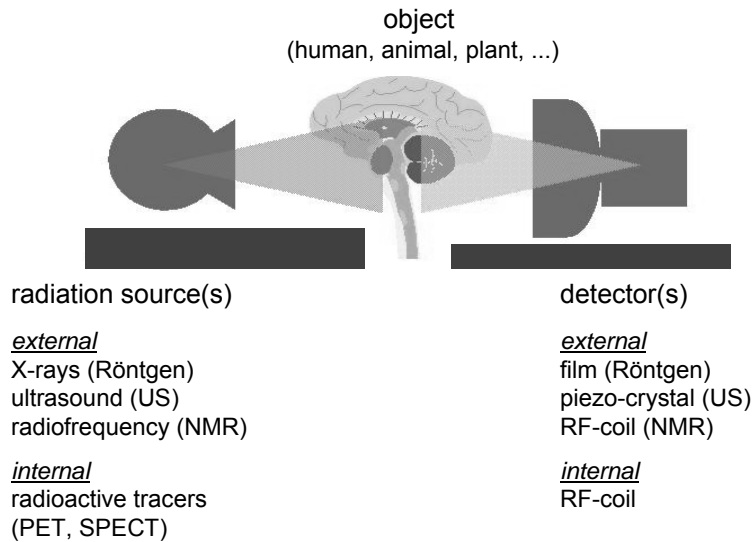


Rank	Innovation	Mean score ^a	Percent of respondents choosing		
			Most	Not most or least	Least
1	MRI and CT scanning	0.878	75.6%	24.4%	0.0%
2	ACE inhibitors	0.767	54.2	44.9	0.9
3	Balloon angioplasty	0.758	53.8	44.0	2.2
4	Statins	0.736	48.0	51.1	0.9
5	Mammography	0.733	47.6	51.6	0.9
6	CABG	0.693	40.4	57.8	1.8
7	Proton pump inhibitors and H2 blockers	0.687	40.0	57.3	2.7
8	SSRIs and recent non-SSRI antidepressants	0.678	39.6	56.4	4.0
9	Cataract extraction and lens implant	0.651	38.2	53.8	8.0
10	Hip and knee replacement	0.649	31.6	66.7	1.8
11	Ultrasonography	0.647	31.1	67.1	1.8
12	Gastrointestinal endoscopy	0.624	28.0	68.9	3.1
13	Inhaled steroids for asthma	0.591	23.6	71.1	5.3
14	Laparoscopic surgery	0.558	20.9	69.8	9.3
15	NSAIDs and Cox-2 inhibitors	0.531	14.2	77.8	8.0
16	Cardiac enzymes	0.498	7.1	85.3	7.6
17	Fluoroquinolones	0.487	6.7	84.0	9.3
18	Recent hypoglycemic agents	0.478	12.9	69.8	17.3
19	HIV testing and treatment	0.444	15.6	57.8	26.7
20	Tamoxifen	0.440	3.1	61.8	35.1
21	PSA testing	0.438	12.9	61.8	25.3
22	Long-acting and parenteral opioids	0.376	8.4	58.2	33.3
23	H. Pylori testing and treatment	0.351	1.8	66.7	31.6
24	Bone densitometry	0.344	4.0	60.9	35.1
25	Third-generation cephalosporins	0.329	1.8	62.2	36.0
26	Calcium channel blockers	0.291	1.8	54.7	43.6
27	IV-conscious sedation	0.289	1.8	54.2	44.0
28	Sildenafil (Viagra)	0.255	0.9	49.3	49.8
29	Nonsedating antihistamines	0.231	1.3	43.6	55.1
30	Bone marrow transplant	0.182	1.3	33.8	64.9
	All 30 innovations	0.520	22.3	59.6	18.2

SOURCE: Authors' analysis of their survey.
NOTES: N = 225. See Exhibit 1 for more details about the thirty innovations studied.
^a Response values: "most" = 1.0; "not most or least" = 0.5; "least" = 0.0.



Diagnostic Imaging: Principal



source: <http://bio.physik.uni-würzburg.de/public/medphys>



Goal

To look into the object without cutting or
destroying (non-invasively) !



Diagnostic Imaging: Definition

definition:

- interaction of energy with biological tissue in order to get spatially resolved information about the physical properties of the underlying biological structure
- energy has to penetrate through the body for interaction (absorption, scattering, ...)

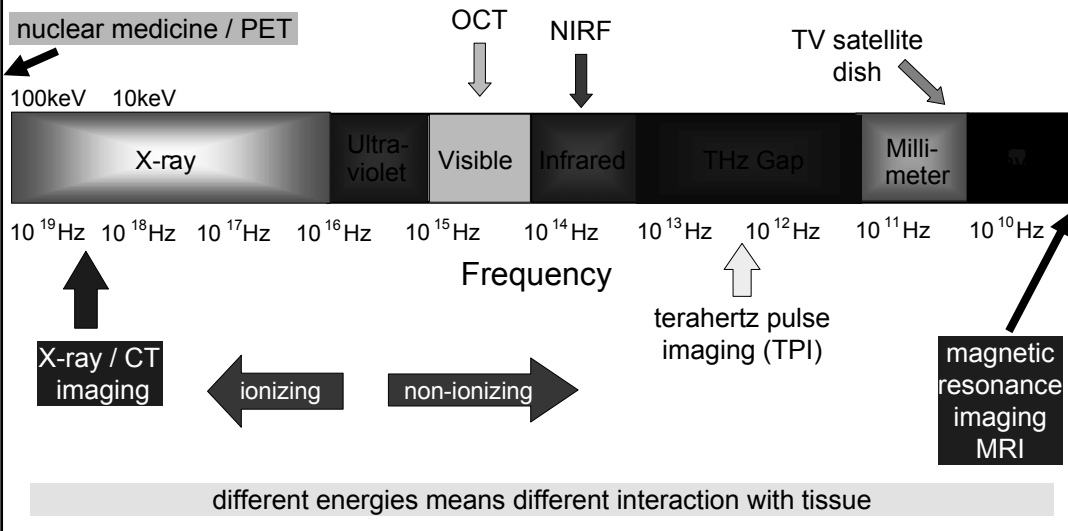
interpretation of imaging information:

- importance of measured physical properties with respect to differentiate between normal and diseased tissue (pathology)
- not fully understood

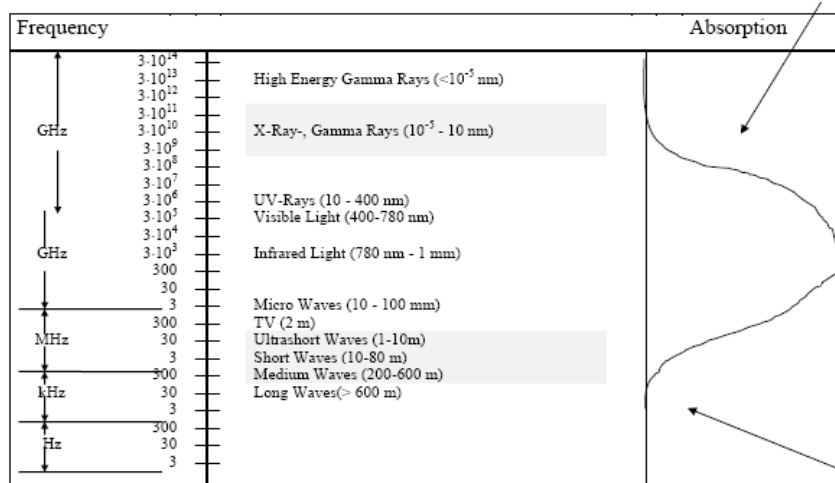


Diagnostic Imaging: Electromagnetic Wave

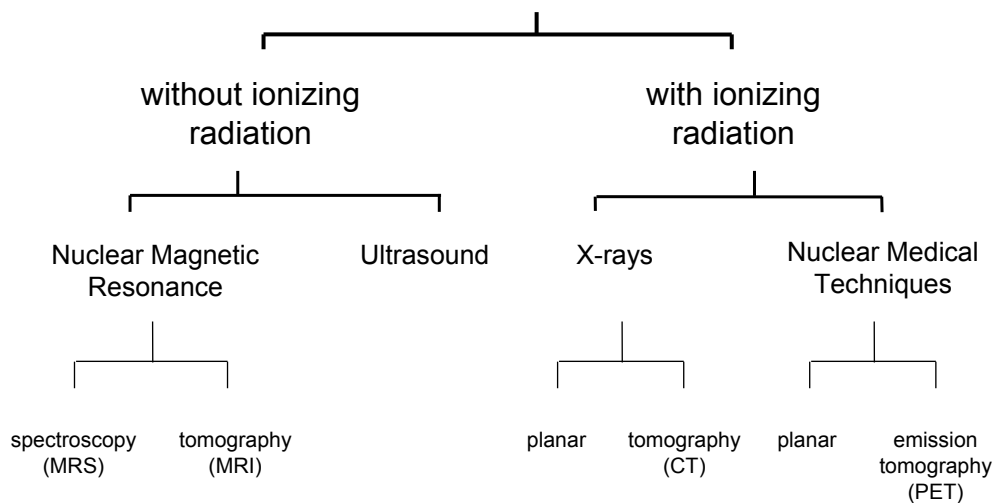
PET and MRI are at the end of the spectrum



Electromagnetic Wave Penetration

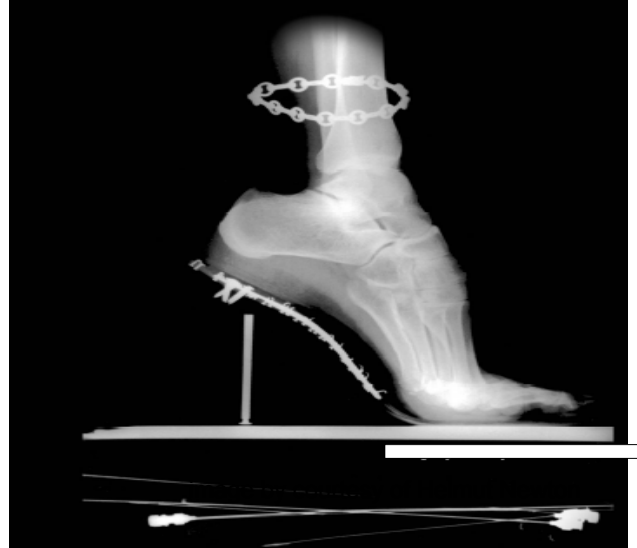

Diagnostic Imaging: Overview





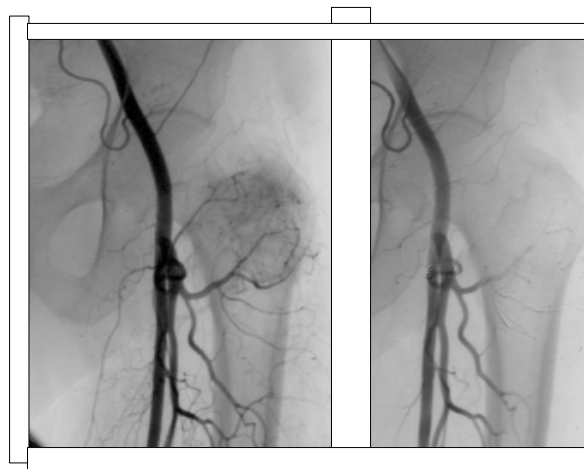
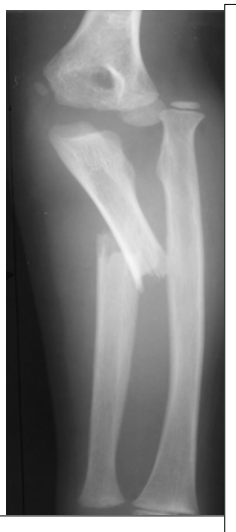Diagnostic Imaging: Anatomy



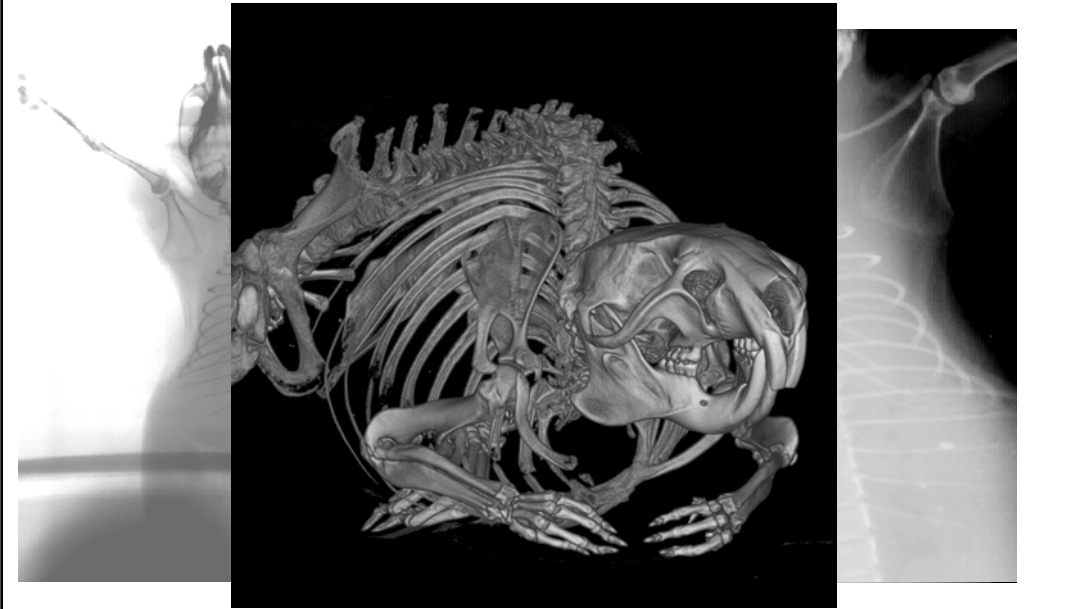source: ECR Newsletter 4/2002



Diagnostic Imaging: Pathology



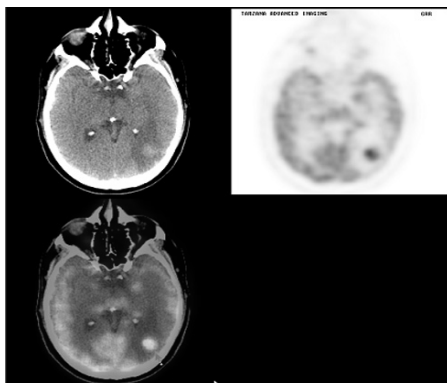
Diagnostic Imaging: Animals



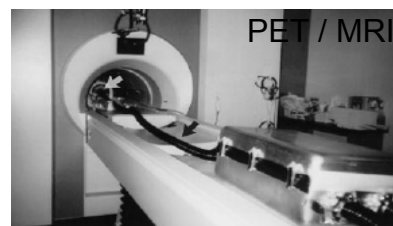Diagnostic Imaging: System Combination



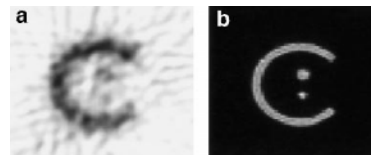
- anatomic / metabolic imaging



The brain shows a large, left posterior / temporal / parietal metastasis. In the transaxial views, a hyper-metabolic area, measuring 2.2 x 2.1 cm with a solid center, is seen, surrounded by edema (arrow on fused image details hypermetabolic area).

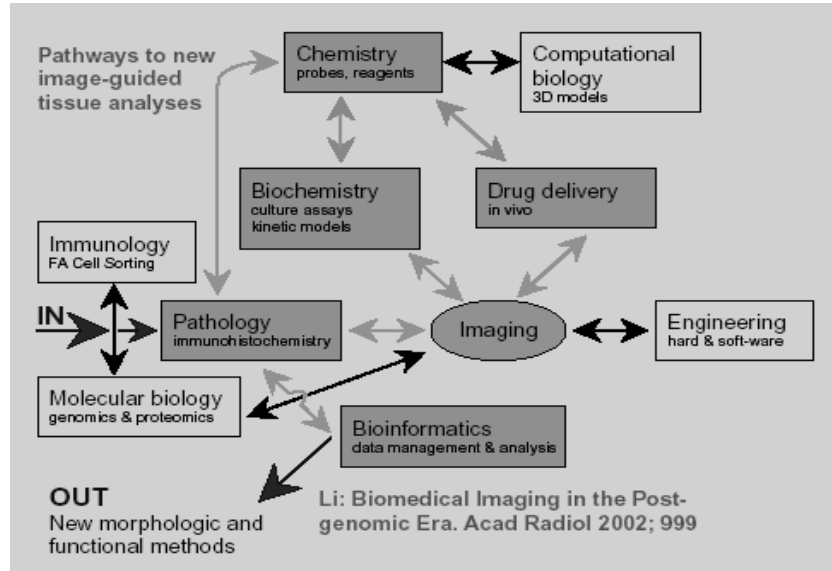


Set-up of the McPET system inside the 1.5 T clinical scanner. McPET's ring of detectors is placed inside the MRI coil (white arrow) and transmits its output to the MC-PMTs, enclosed in the RF-shielded box in the foreground, via doubleclad optical fibers (black arrow).



A pair of PET (a) and MR (b) images contemporaneously obtained from the C-phantom at 1.5 T.

Biomedical Imaging



source: ECR Newsletter 4/2002

Diagnostic Imaging: Field of Application



main focus of diagnostic imaging

- diagnostic
- therapy-planning and -monitoring
- screening
- monitoring of interventions

Diagnostic Imaging: Properties



	X-Ray	CT	MR	US
imaging of				
bone	+++	+++	+	-
soft tissue	- / +	-	++	+
vessel	++	++	++	+
function	-	-	++	++
volume	-	++	++	+
real-time	*	+	+	++
psychological stress	small	medium	high	small
physical stress	high	high	small	small
invasiv	no	no	no	no
costs (EUR)	ca. 40	ca. 100	ca. 400	ca. 10